



ELSEVIER

Contents lists available at ScienceDirect

The Ocular Surface

journal homepage: www.elsevier.com/locate/jtos

Original Research

Therapeutic efficacy of intense pulsed light in patients with refractory meibomian gland dysfunction

Reiko Arita^{a,d,*}, Shima Fukuoka^{b,d}, Naoyuki Morishige^{c,d}^a Itoh Clinic, Saitama, Japan^b Omiya Hamada Eye Clinic, Saitama, Japan^c Division of Cornea and Ocular Surface, Oshima Eye Hospital, Fukuoka, Japan^d Lid and Meibomian Gland Working Group (LIME), Japan

ARTICLE INFO

Keywords:

Dry eye
Intense pulsed light
Meibomian gland dysfunction
Meibomian gland expression
Meibum

ABSTRACT

Purpose: To evaluate the efficacy and safety of intense pulsed light (IPL) combined with meibomian gland expression (MGX) for treatment of refractory meibomian gland dysfunction (MGD).

Methods: Ninety eyes of 45 patients were randomly assigned to receive either the combination of IPL and MGX or MGX alone (control). Each eye underwent eight treatment sessions at 3-week intervals. Parameters were evaluated before and during treatment as well as at 3–11 weeks after the last treatment session. Measured parameters included the Standard Patient Evaluation of Eye Dryness (SPEED) questionnaire score, noninvasive breakup time (NIBUT), fluorescein breakup time (BUT), lipid layer grade, lipid layer thickness (LLT), lid margin abnormalities, corneal and conjunctival fluorescein staining (CFS) score, meibum grade, and meiboscore.

Results: A significant improvement in lipid layer grade was apparent in the IPL-MGX group from 6 to 32 weeks after treatment onset (adjusted $P < 0.001$) but was not observed in the control group. The IPL-MGX group also showed significant improvements in LLT, NIBUT, BUT, lid margin abnormalities, and meibum grade compared with the control group at 24 and 32 weeks (adjusted $P < 0.001$) as well as significant improvements in the SPEED score at 32 weeks (adjusted $P = 0.044$) and in CFS score at 24 (adjusted $P = 0.015$) and 32 (adjusted $P = 0.006$) weeks.

Conclusions: The combination of IPL and MGX improved homeostasis of the tear film and ameliorated ocular symptoms in patients with refractory MGD and is thus a promising modality for treatment of this condition.

1. Introduction

Dry eye disease is defined as a multifactorial disease of the ocular surface characterized by a loss of homeostasis of the tear film and accompanied by ocular symptoms that result in part from tear film instability and hyperosmolarity, ocular surface inflammation and damage, and neurosensory abnormalities [1]. Intense pulsed light (IPL) therapy has been shown to ameliorate ocular symptoms, tear film instability, and ocular surface inflammation and damage in dry eye associated with meibomian gland dysfunction (MGD) [2–14]. We previously showed that the Kowa DR-1 α tear interferometer is able to evaluate the balance between the lipid and aqueous layers of the tear film [15]. These two components compensate for each other to maintain homeostasis of the tear film [15,16], but the effect of IPL treatment on the balance between them has been unknown.

MGD is a chronic abnormality of meibomian glands characterized by terminal duct obstruction or qualitative or quantitative changes in glandular secretion [17]. It gives rise to an imbalance in the tear film due to a deficiency of the lipid layer. MGD is the leading cause of evaporative dry eye [17], and it accounts for most cases of dry eye overall [18]. The goal of MGD therapy is to provide a long-term amelioration of symptoms by improving the quality of meibum or increasing meibum flow—and thereby normalizing the balance between the lipid and aqueous layers of the tear film and restoring tear film stability—as well as by reducing inflammation. Common therapies include the application of a warm compress, the practice of lid hygiene, dietary supplementation with omega-3 fatty acids, forced meibum expression [17], intraductal probing [19], automated thermal pulsation [20], and the administration of preservative-free eyedrops, lipid-containing eyedrops, diquafosol eyedrops [21], topical cyclosporine or

Abbreviations/acronyms: IPL, intense pulsed light; MGD, meibomian gland dysfunction; MGX, meibomian gland expression; LLT, lipid layer thickness; NIBUT, noninvasive breakup time; BUT, breakup time; CFS, corneal and conjunctival fluorescein staining; SPEED, Standard Patient Evaluation of Eye Dryness

* Corresponding author. Department of Ophthalmology, Itoh Clinic, 626-11 Minami-Nakano, Minumaku, Saitama, Saitama, 337-0042, Japan.

E-mail address: ritoh@za2.so-net.ne.jp (R. Arita).

<https://doi.org/10.1016/j.jtos.2018.11.004>

Received 13 July 2018; Received in revised form 22 September 2018; Accepted 7 November 2018

1542-0124/ © 2018 The Authors. Published by Elsevier Inc. This is an open access article under the CC BY-NC-ND license (<http://creativecommons.org/licenses/by-nc-nd/4.0/>).

azithromycin, and oral doxycycline. Despite the variety of treatment options available, however, patients often do not experience complete or long-term relief of symptoms.

IPL therapy is widely adopted in the cosmetic industry as well as therapeutically for the removal of hypertrichosis, benign cavernous hemangiomas or venous malformations, telangiectasia, port wine stains, and pigmented lesions [22]. A systematic review showed that IPL is an effective and well-tolerated treatment option for a range of dermatologic conditions including telangiectasia and facial erythema [23]. An improvement in ocular surface health was observed serendipitously in individuals undergoing IPL for the dermatologic manifestations of rosacea, leading to interest in IPL as a potential therapy for MGD [24]. IPL alone was thus found to improve subjective symptoms and objective findings [2,6], whereas the combination of IPL and meibomian gland expression (MGX) improved dry eye symptoms and gland function [4,5,7,14], in patients with MGD.

We previously showed that the combination of IPL and MGX ameliorated symptoms and improved the condition of the tear film in a single-arm study with patients with refractory MGD [25]. To evaluate further the efficacy and safety of combined therapy with IPL and MGX in patients with refractory MGD, we have now performed a prospective, controlled study to examine the comprehensive effects of this approach in comparison with MGX alone.

2. Methods

The study was approved by the Institutional Review Board of Itoh Clinic, adhered to the tenets of the Declaration of Helsinki, and was performed at Itoh Clinic from May 2016 to August 2017. Written informed consent was obtained from each patient before enrollment in the study (UMIN00022747).

2.1. Subjects

Patients with refractory MGD attending Itoh Clinic were enrolled. Inclusion criteria were as follows [1]: age of at least 20 years [2]; diagnosis of MGD according to Japanese MGD diagnostic criteria [26] including ocular symptoms, plugged gland orifices, vascularity of lid margins, irregularity of lid margins, and decreased meibum quality and quantity (Shimazaki grading) [3,27] Fitzpatrick skin type of 1–4 according to sun sensitivity and appearance of the skin [28], as well as the absence of active lesions, skin cancer, or specific skin pathology that would exclude treatment with IPL; and [4] refractory MGD as defined by the failure to respond over a period of at least 2 years to at least three types of conventional therapy prescribed in Japan, including topical or systemic anti-inflammatory therapy, topical or systemic antibiotic therapy, lubricant eyedrops or topical ointment, automated thermal pulsation, and intraductal probing. Given that most patients with MGD have applied a warm compress or practiced lid hygiene at home regardless of disease severity, these home-care remedies were not included as failed therapies in the present study.

2.2. Experimental design

Refractory MGD patients were randomly assigned to receive either IPL with MGX (IPL-MGX) or MGX alone as a control. Each patient underwent a series of eight treatment sessions at 3-week intervals. After the eight treatment sessions, each patient underwent three follow-up examinations over the course of 11 weeks (Fig. 1). All patients used a warming compress once a day and diquafosol eyedrops (Diquas; Santen, Osaka, Japan) six times a day during the study including the follow-up period. Clinical assessment was performed as described below.

2.3. Clinical assessment

The safety of IPL-MGX treatment was evaluated by measurement of

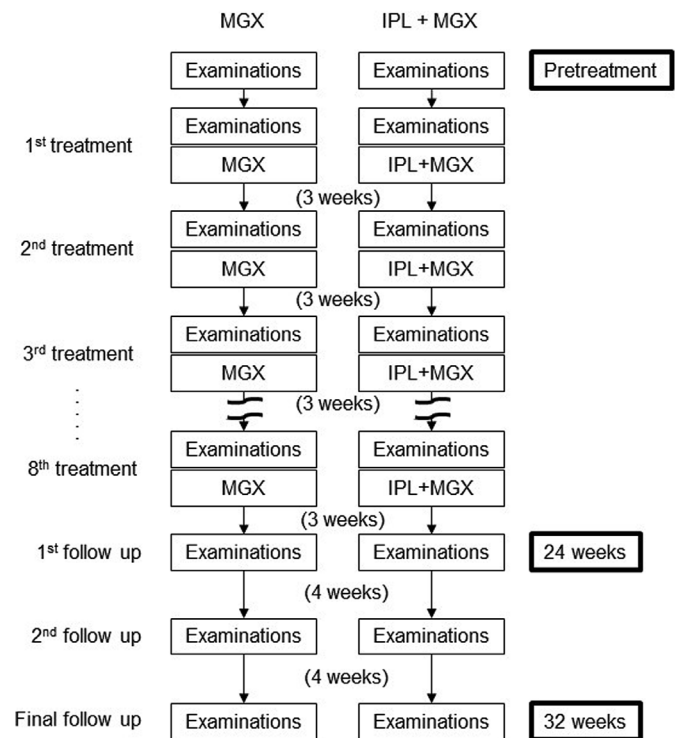


Fig. 1. Treatment and follow-up protocol for the intense pulsed light (IPL)–meibomian gland expression (MGX) and MGX (control) groups. Each patient underwent a series of eight treatment sessions at 3-week intervals and was subjected to clinical assessment before treatment at each visit as well as 3, 7, and 11 weeks after the final treatment.

visual acuity, lens opacity, and intraocular pressure as well as by fundus examination before and 32 weeks after the first treatment session. For evaluation of treatment efficacy, the following parameters were measured before each treatment and at each follow-up visit: lipid layer thickness (LLT) of the tear film as determined with a LipiView instrument (TearScience, Morrisville, NC) [29], noninvasive breakup time (NIBUT) of the tear film and tear interferometric fringe pattern as determined with the DR-1 α tear interferometer (Kowa, Aichi, Japan) [15], lid margin abnormalities [30] as observed with a slitlamp microscope, breakup time (BUT) of the tear film as determined by fluorescein staining as well as the corneal and conjunctival staining (CFS) score [31], meibum grade(27) as determined by slitlamp microscopy, morphological changes of meibomian glands as assessed by noninvasive meibography (meiboscore) [32], and tear production as measured by the Schirmer test performed without anesthetic [33]. Symptoms were also assessed with the Standard Patient Evaluation of Eye Dryness (SPEED) [34] validated questionnaire.

2.4. Combined treatment with IPL and MGX

Before the first IPL treatment, each patient underwent Fitzpatrick skin typing [28], and the IPL machine (M22; Lumenis, Yokneam, Israel) was adjusted to the appropriate setting (range of 11–14 J/cm²). At each treatment session, both eyelids were closed and sealed with IPL-Aid disposable eye shields (Honeywell Safety Products, Smithfield, RI). After generous application of ultrasonic gel to the treatment area, patients received ~13 light pulses (with slightly overlapping areas of application) from the left preauricular area, across the cheeks and nose, to the right preauricular area, with the treated area reaching up to the inferior boundary of the eye shields. The procedure was then repeated in a second pass. Immediately after the IPL treatment, MGX was performed on both upper and lower eyelids of each eye with an Arita Meibomian Gland Compressor (Katena, Denville, NJ). Pain was

minimized during this procedure by topical application of 0.4% oxybuprocaine hydrochloride.

2.5. Control (MGX only) treatment

MGX was performed on both upper and lower eyelids of each eye with an Arita Meibomian Gland Compressor (Katena) every 3 weeks. Eyedrops containing 0.4% oxybuprocaine hydrochloride were administered to minimize pain.

2.6. Statistical analysis

Sample size was calculated on the basis of assumed mean differences in LLT of 27.4 and 29.6 nm between the IPL-MGX group and the control group at 24 and 32 weeks after treatment onset, respectively, with corresponding SD values of 17.9 and 17.2 nm; in NIBUT of 3.9 and 4.8 s between the IPL-MGX and control groups at 24 and 32 weeks after treatment onset, respectively, with corresponding SD values of 0.7 and 0.9 s; and in meibum grade of 1.1 and 1.4 between the two groups at 24 and 32 weeks after treatment onset, respectively, with corresponding SD values of 0.6 and 0.7. These assumed differences were based on the findings of a pilot study with 20 eyes of 10 patients in each group. With these assumptions, a sample size of 24 eyes per group would yield a power of > 90% to show a significant difference with a two-sample *t*-test. We chose an α level of 0.025 to ensure an overall type I error rate of 0.05 according to the Bonferroni procedure. After testing for homogeneity of variance, we used the paired Student's *t*-test to compare variables between before and either 24 or 32 weeks after treatment onset as well as the unpaired *t*-test to compare pretreatment or post-treatment variables between the control and IPL-MGX groups. Comparison of NIBUT, BUT, SPEED score, plugging, and vascularity between before and various times after the onset of treatment was performed with the paired *t*-test, whereas that of tear interferometric fringe pattern between before and after treatment was performed with Fisher's exact test. Bonferroni's correction was applied to correct for multiple comparisons. Adjusted *P* values were obtained by multiplying *P* values by the number of comparisons in the Bonferroni's correction. Statistical analysis was performed with JMP Pro version 11 software (SAS, Cary, NC). All statistical tests were two sided, and a *P* value of < 0.05 was considered statistically significant.

3. Results

Patient demographics are shown in Table 1. Ninety eyes of 45 patients were enrolled in the study. Three patients in the MGX (control) group subsequently withdrew from the study because of pain during the procedure, leaving a total of 20 patients in the MGX group and 22 patients in the IPL-MGX group.

3.1. Safety of IPL-MGX

Visual acuity, intraocular pressure, lens opacity, and fundus condition showed no change between before and 32 weeks after treatment

onset in either treatment group (data not shown).

3.2. Efficacy of IPL-MGX

The characteristics of the eyes in the IPL-MGX group and the control group before as well as 24 and 32 weeks after treatment onset are shown in Table 2. No significant differences in parameters were detected between the two groups before treatment. The SPEED score was significantly reduced at both 24 and 32 weeks after treatment onset in both groups. Whereas the SPEED score did not differ significantly between the two groups at 24 weeks, it was significantly smaller in the IPL-MGX group than in the control group at 32 weeks. Significant increases in NIBUT and BUT as well as significant decreases in plugging and meibum grade were also apparent at both time points after treatment initiation in both groups. However, the eyes in the IPL-MGX group showed a significantly better improvement in NIBUT, BUT, plugging, and meibum grade compared with those in the control group. A significant increase in LLT as well as significant decreases in vascularity and CFS score were detected at both time points after treatment only in the IPL-MGX group. Irregularity, meiboscore, and Schirmer test value at 24 and 32 weeks after treatment onset did not differ significantly between the control and IPL-MGX groups. An improvement in SPEED score, NIBUT, BUT, plugging, meibum grade, LLT, vascularity, and CFS score was thus still apparent at 11 weeks after the final treatment session in the IPL-MGX group, with such an improvement in LLT, vascularity, and CFS score not being observed in the control group.

The time courses of the SPEED score, NIBUT, BUT, plugging, and vascularity before, during, and after treatment in the two groups are shown in Figs. 2–6, respectively. Although the SPEED score, NIBUT, and BUT were significantly improved in the control group during and after treatment compared with before treatment, these parameters did not achieve the cutoff values for diagnosis of dry eye. The SPEED score in the IPL-MGX group was decreased significantly from 3 to 32 weeks after treatment onset compared with before treatment, whereas that in the control group was significantly reduced from 15 to 32 weeks (Fig. 2). Significant increases in NIBUT (Fig. 3) and BUT (Fig. 4) were apparent during and after treatment in both groups. The IPL-MGX group also showed a significant decrease in plugging (Fig. 5) and vascularity (Fig. 6) from 3 to 32 weeks after treatment onset, whereas a significant decrease in plugging was not apparent until 6 weeks in the control group.

Finally, the time course of lipid layer grade(15) in the two treatment groups is shown in Fig. 7. The tear interferometric fringe pattern in the control group maintained its crystal-like appearance, indicative of a thin lipid layer, both during and after treatment. A significant improvement in lipid layer dynamics, with a shift in interferometric pattern from crystal-like to pearl-like appearance, indicative of the normal tear film condition, was apparent from 6 to 32 weeks after treatment onset in the IPL-MGX group.

4. Discussion

This is the first prospective and randomized study to show that a

Table 1
Characteristics of the study subjects in the intense pulsed light (IPL)–meibomian gland expression (MGX) and MGX (control) groups.

Characteristic	IPL-MGX group (n = 22)	Control (MGX) group (n = 20)
Age (years), mean \pm SD (range)	61.0 \pm 18.0 (23–81)	61.9 \pm 12.2 (39–78)
Sex (male/female)	9 (41%)/13 (59%)	8 (40%)/12 (60%)
Duration of MGD (years), mean \pm SD (range)	9.6 \pm 5.9 [2–21]	8.7 \pm 4.5 [2–15]
At least three meibomian gland dropouts in one eyelid	17 (77.3%)	15 (75%)
History of contact lens wear	12 (54.5%)	12 (60.0%)
Coincidence of ADDE	12 (54.5%)	8 (40%)
Previous ocular surgery, blepharoplasty, or blepharoplasty	6 (27.3%)	8 (40%)

MGD, meibomian gland dysfunction; ADDE, aqueous-deficient dry eye.

Table 2

Characteristics of intense pulsed light (IPL)-meibomian gland expression (MGX) and MGX (control) groups before as well as 24 and 32 weeks after treatment onset.

Characteristic	Group	Pretreatment		24 weeks after treatment onset				32 weeks after treatment onset			
		Mean \pm SD	Adjusted P value for	Mean \pm SD	Mean change \pm SE	Adjusted P value vs. Pretreatment	Adjusted P value for IPL-MGX vs. control	Mean \pm SD	Mean change \pm SE	Adjusted P value vs. Pretreatment	Adjusted P value for IPL-MGX vs. control
SPEED score (0–28)	IPL-MGX	14.7 \pm 3.4	0.39	5.9 \pm 6.0	-8.3 \pm 0.9	< 0.001**	0.24	5.5 \pm 5.4	-9.2 \pm 0.9	< 0.001**	0.044*
	Control	12.7 \pm 4.8		9.1 \pm 3.8	-3.7 \pm 0.6	< 0.001**		9.2 \pm 3.9	-3.6 \pm 0.6	< 0.001**	
LLT (nm)	IPL-MGX	46.0 \pm 10.0	1.00	67.3 \pm 17.7	21.3 \pm 2.6	< 0.001**	< 0.001**	66.1 \pm 18.0	20.1 \pm 2.7	< 0.001**	< 0.001**
	Control	48.8 \pm 17.3		50.5 \pm 16.9	1.8 \pm 1.9	0.7		49.5 \pm 16.4	0.8 \pm 1.7	1.00	
Plugging (0–3)	IPL-MGX	1.9 \pm 0.8	0.57	0.2 \pm 0.4	-1.7 \pm 0.1	< 0.001**	< 0.001**	0.1 \pm 0.3	-1.8 \pm 0.1	< 0.001**	< 0.001**
	Control	2.2 \pm 0.8		1.7 \pm 0.7	-0.5 \pm 0.1	< 0.001**		1.7 \pm 0.7	-0.5 \pm 0.1	< 0.001**	
Vascularity (0–3)	IPL-MGX	1.5 \pm 0.8	1.00	0.2 \pm 0.4	-1.3 \pm 0.1	< 0.001**	< 0.001**	0.2 \pm 0.4	-1.3 \pm 0.1	< 0.001**	< 0.001**
	Control	1.4 \pm 0.9		1.4 \pm 0.9	0.0 \pm 0.0			1.4 \pm 0.9	0.0 \pm 0.0		
Irregularity (0–2)	IPL-MGX	0.9 \pm 0.9	1.00	0.8 \pm 0.8	-0.1 \pm 0.0	0.17	0.84	0.8 \pm 0.8	-0.1 \pm 0.1	0.047*	0.5
	Control	1.1 \pm 0.8		1.0 \pm 0.8	0.0 \pm 0.0	0.65		1.0 \pm 0.8	0.0 \pm 0.0	0.65	
Meiboscore (0–6)	IPL-MGX	4.5 \pm 1.3	0.82	4.2 \pm 1.2	-0.3 \pm 0.1	0.003*	1	4.2 \pm 1.2	-0.3 \pm 0.1	< 0.001**	1
	Control	4.2 \pm 1.1		4.2 \pm 1.1	0.0 \pm 0.0	0.65		4.2 \pm 1.1	0.0 \pm 0.0	0.65	
Meibum grade (0–3)	IPL-MGX	2.2 \pm 0.8	0.83	0.3 \pm 0.6	-1.9 \pm 0.1	< 0.001**	< 0.001**	0.3 \pm 0.6	-1.8 \pm 0.1	< 0.001**	< 0.001**
	Control	2.0 \pm 0.5		1.4 \pm 0.7	-0.6 \pm 0.1	< 0.001**		1.8 \pm 0.7	-0.3 \pm 0.1	0.002*	
NIBUT (s)	IPL-MGX	2.5 \pm 1.2	1.00	6.6 \pm 2.4	4.1 \pm 0.3	< 0.001**	< 0.001**	7.0 \pm 2.7	4.5 \pm 0.4	< 0.001**	< 0.001**
	Control	2.4 \pm 1.2		3.3 \pm 0.7	0.9 \pm 0.2	< 0.001**		3.0 \pm 0.9	0.6 \pm 0.2	< 0.001**	
BUT (s)	IPL-MGX	2.9 \pm 0.9	1.00	6.2 \pm 2.4	3.3 \pm 0.4	< 0.001**	< 0.001**	6.6 \pm 2.4	3.7 \pm 0.4	< 0.001**	< 0.001**
	Control	2.8 \pm 1.1		3.7 \pm 0.9	0.9 \pm 0.2	< 0.001**		3.1 \pm 1.0	0.4 \pm 0.1	0.005*	
CFS score (0–9)	IPL-MGX	1.1 \pm 1.4	0.68	0.2 \pm 0.4	-1.0 \pm 0.2	< 0.001**	0.015*	0.1 \pm 0.3	-1.0 \pm 0.2	< 0.001**	0.006*
	Control	0.8 \pm 1.1		0.8 \pm 1.2	0.0 \pm 0.1	1		0.8 \pm 1.2	0.0 \pm 0.1	1.0	
Schirmer value (mm)	IPL-MGX	8.5 \pm 7.7	1.00	8.8 \pm 7.0	0.3 \pm 0.8	1	0.69	8.4 \pm 5.9	-0.1 \pm 0.6	1.00	0.5
	Control	9.6 \pm 9.5		11.0 \pm 9.2	1.4 \pm 0.5	0.003*		10.9 \pm 9.5	1.3 \pm 0.5	0.026*	

SPEED, Standard Patient Evaluation of Eye Dryness; LLT, lipid layer thickness; NIBUT, noninvasive breakup time; BUT, breakup time; CFS, corneal-conjunctival staining.

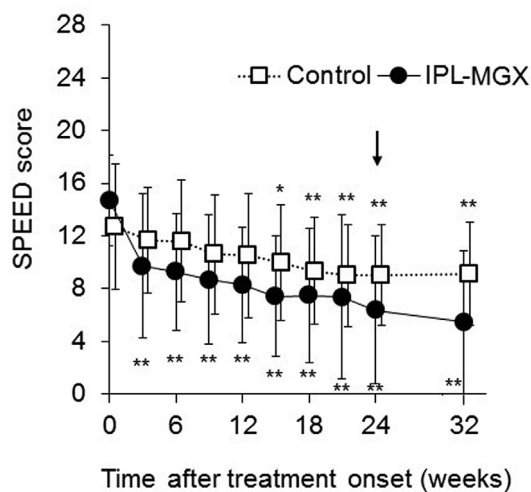


Fig. 2. Time course of the Standard Patient Evaluation of Eye Dryness (SPEED) score before, during, and after treatment in the intense pulsed light (IPL)-meibomian gland expression (MGX) and MGX (control) groups. Data are means \pm SD ($n = 22$ and 20 , respectively). *Adjusted $P < 0.05$, **adjusted $P < 0.001$ versus corresponding pretreatment (time 0) value (paired t -test with Bonferroni's correction for nine comparisons). Arrow indicates first examination of the follow-up period.

series of IPL-MGX treatment sessions significantly improved subjective symptoms and objective signs compared with MGX alone in patients with refractory MGD. We evaluated a total of 12 parameters including those related to meibomian glands and the lipid layer of the tear film both before treatment as well as at each of the eight treatment sessions and for up to 11 weeks after the final treatment. Our Results thus indicate that IPL-MGX is a promising therapeutic approach for patients

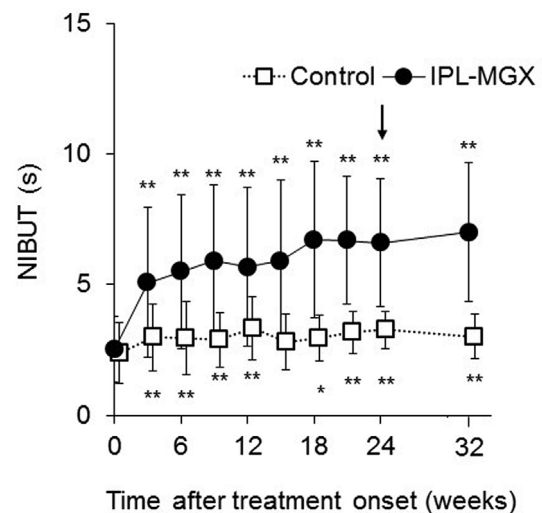


Fig. 3. Time course of tear film noninvasive breakup time (NIBUT) before, during, and after treatment in the intense pulsed light (IPL)-meibomian gland expression (MGX) and MGX (control) groups. Data are means \pm SD ($n = 44$ and 40 , respectively). *Adjusted $P < 0.05$, **adjusted $P < 0.001$ versus corresponding pretreatment (time 0) value (paired t -test with Bonferroni's correction for nine comparisons). Arrow indicates first examination of the follow-up period.

with refractory MGD.

Both IPL-MGX and MGX alone resulted in a significant improvement in various measured parameters compared with pretreatment values. IPL-MGX thus significantly improved the SPEED score and CFS score, tear film-related parameters such as NIBUT, LLT, and BUT, eyelid conditions such as vascularity and plugging, as well as both the

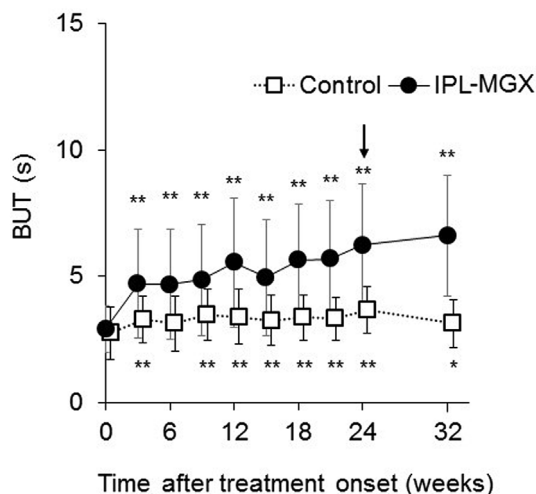


Fig. 4. Time course of tear film breakup time (BUT) measured by fluorescein staining before, during, and after treatment in the intense pulsed light (IPL)–meibomian gland expression (MGX) and MGX (control) groups. Data are means \pm SD ($n = 44$ and 40 , respectively). *Adjusted $P < 0.05$, **adjusted $P < 0.001$ versus corresponding pretreatment (time 0) value (paired t -test with Bonferroni's correction for nine comparisons). Arrow indicates first examination of the follow-up period.

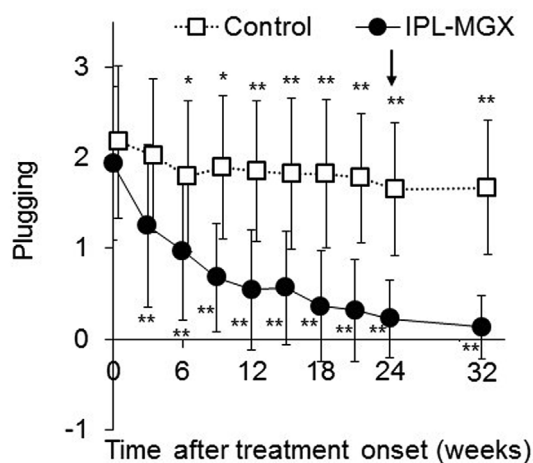


Fig. 5. Time course of plugging before, during, and after treatment in the intense pulsed light (IPL)–meibomian gland expression (MGX) and MGX (control) groups. Data are means \pm SD ($n = 44$ and 40 , respectively). *Adjusted $P < 0.05$, **adjusted $P < 0.001$ versus corresponding pretreatment (time 0) value (paired t -test with Bonferroni's correction for nine comparisons). Arrow indicates first examination of the follow-up period.

meiboscore and meibum grade at 24 weeks after treatment initiation (3 weeks after the final treatment session). These effects remained apparent at 32 weeks after the onset of treatment (11 weeks after the final treatment session). Although MGX alone also improved several tear film and eyelid parameters at both 24 and 32 weeks after treatment onset, the effects of IPL-MGX treatment on NIBUT, LLT, plugging, vascularity, BUT, CFS score, and meibum grade at both 24 and 32 weeks were significantly greater than those of MGX alone. The SPEED score was also reduced to a significantly greater extent at 32 weeks by IPL-MGX compared with MGX alone. Furthermore, LLT, vascularity, CFS score, and the meiboscore were improved significantly only in the IPL-MGX group. Irregularity, which is thought to be the irreversible result of traction after meibomian gland dropout, was ameliorated in the IPL-MGX group at 32 weeks, whereas the Schirmer test value, which reflects tear fluid production, was increased in the control group at both 24 and

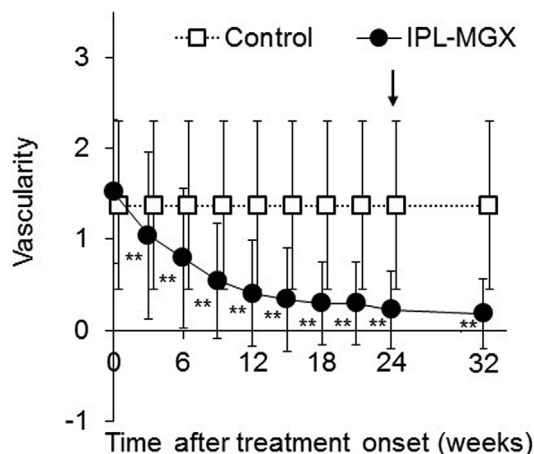


Fig. 6. Time course of vascularity before, during, and after treatment in the intense pulsed light (IPL)–meibomian gland expression (MGX) and MGX (control) groups. Data are means \pm SD ($n = 44$ and 40 , respectively). **Adjusted $P < 0.001$ versus corresponding pretreatment (time 0) value (paired t -test with Bonferroni's correction for nine comparisons). Arrow indicates first examination of the follow-up period.

32 weeks. However, neither irregularity nor the Schirmer test value differed between the two groups at either time point.

The SPEED score was significantly improved from a mean value of 14.7 to 5.9 and from 12.7 to 9.1 between before and 24 weeks after treatment initiation in the IPL-MGX and control groups, respectively. At 32 weeks, the mean values were 5.5 and 9.2 in the IPL-MGX and control groups, respectively. The cutoff value of the SPEED score for evaluation of dry eye disease is 9 [35], with individuals with a score of 9 or higher thus complaining of ocular symptoms of dry eye. Whereas the amelioration of symptoms by MGX alone was statistically significant, it might therefore not have been clinically effective. IPL-MGX treatment improved ocular symptoms to such an extent that the SPEED score was substantially below the cutoff value for dry eye. A similar pattern was observed for NIBUT (cutoff value of 5 s) [15] and BUT (cutoff value of 5 s) [36], with IPL-MGX improving these parameters from the abnormal to normal range whereas MGX alone induced significant but clinically ineffective changes.

MGX was first described in 1921 by Gifford [37] as an effective method for rehabilitation of meibomian glands and amelioration of dry eye symptoms. Korb and Greiner showed that MGX improved both LLT and symptoms in 10 patients with MGD [38]. More recently, Lee et al. demonstrated efficacy of weekly mechanical squeezing of meibomian glands for MGD patients [39]. In the present study, we also found that MGX alone resulted in significant improvements in various parameters. However, MGX causes pain in some patients. Indeed, three patients withdrew from the control arm of the present study because of such pain. Of interest, MGX was acceptable after IPL for all patients enrolled in the IPL-MGX arm, possibly because IPL softens meibum and thereby reduces the pain associated with MGX.

There are several potential mechanisms for the amelioration of ocular surface symptoms and signs by IPL in MGD patients. First, IPL warms meibomian glands through the thin periocular skin and thereby melts meibum [8,24]. Second, the IPL device emits energy that is absorbed by chromophores in hemoglobin and thereby closes abnormal vessels in the eyelid margin and adjacent conjunctiva and prevents the release of inflammatory factors by these vessels [40,41]. The concentrations of inflammatory factors including interleukin-17A, interleukin-6, and prostaglandin E_2 in tear fluid were recently found to be reduced by IPL therapy [10]. Third, IPL may relieve inflammatory or neurogenic pain [42]. And fourth, IPL treatment can result in an immediate reduction in bacterial load of the eyelid margin and surrounding adnexa and in a consequent attenuation of inflammation [43].

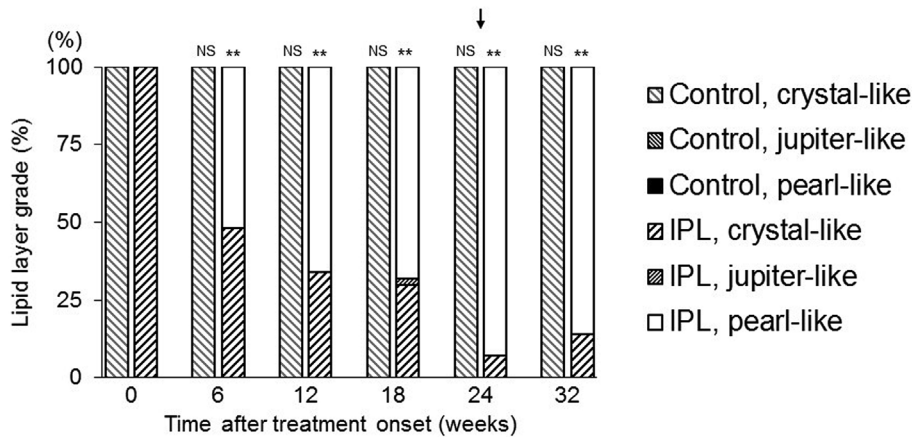


Fig. 7. Time course of lipid layer grade before, during, and after treatment in the intense pulsed light (IPL)–meibomian gland expression (MGX) and MGX (control) groups. Data represent the percentage of eyes ($n = 44$ and 40 , respectively). **Adjusted $P < 0.001$; NS, not significant versus corresponding pretreatment (time 0) value (Fisher's exact test with Bonferroni's correction for five comparisons). Arrow indicates the first examination of the follow-up period.

We found that IPL-MGX improved vascularity, whereas MGX alone did not, with this effect of IPL-MGX possibly being due to the anti-inflammatory effect of IPL.

In the present study, we applied eight sessions of IPL-MGX treatment for patients with refractory MGD. An average of seven sessions of IPL treatment was previously shown to be required for symptomatic improvement in patients with mild dry eye [24]. Given that we enrolled only patients with refractory MGD, we speculated that more than seven sessions of IPL might be necessary. Our Results show that 66% and 93% of subjects had recovered a balance in tear film components, as indicated by the pearl-like appearance of the tear interferometric pattern, after four and eight sessions of IPL-MGX, respectively. This improvement in tear film homeostasis remained apparent 32 weeks after treatment onset. NIBUT is characteristically reduced in patients with MGD [44], and we observed an increase in mean NIBUT from 2.5 to 6.6 s after eight IPL-MGX sessions (24 weeks after treatment onset) and to 7.0 s after 11 weeks of follow-up. These changes represent a meaningful clinical improvement, given that we previously showed the cutoff value of NIBUT as measured with the DR-1 α tear interferometer to be 5 s [15]. In contrast, MGX alone did not improve lipid layer dynamics as reflected by the tear interferometric pattern. We did not detect any adverse effects such as a burning sensation in any of the subjects treated with IPL-MGX. Although further studies will be required to confirm and extend our findings, the results of the present study suggest that eight IPL-MGX sessions may be necessary for the effective treatment of refractory MGD.

With regard to limitations of our study, the number of enrolled patients may not be sufficiently large to determine an adequate protocol for the treatment of refractory MGD. Furthermore, given that the skin type of most Japanese individuals is classified as Fitzpatrick type 3, the reactivity of the skin to light or ultraviolet may differ between the study patients and individuals of other ethnicities. Similar studies with patients of other ethnic groups will thus be required. In addition, the mechanism underlying the effectiveness of IPL-MGX treatment was not demonstrated.

In conclusion, we have shown that the combination of IPL and MGX is safe and effective for the treatment of refractory MGD. Although further studies will be necessary to develop and establish this treatment procedure for the clinic, our Results suggest that repeated IPL-MGX sessions improve homeostasis of tear film components in patients with refractory MGD.

Funding

This research did not receive any specific grant from funding agencies in the public, commercial, or not-for-profit sectors.

Disclosure

R.A. holds patents on the noncontact meibography technique described in this manuscript (Japanese patent registration no. 5281846; U.S. patent publication no. 2011–0273550A1; European patent publication no. 2189108A1), is a consultant for Kowa Company (Aichi, Japan) and Lumenis Japan (Tokyo, Japan), and has received financial support from TearScience (Morrisville, NC). The other authors declare no potential conflict of interest.

Appendix A. Supplementary data

Supplementary data to this article can be found online at <https://doi.org/10.1016/j.jtos.2018.11.004>.

References

- [1] Craig JP, Nichols KK, Akpek EK, Caffery B, Dua HS, Joo CK, et al. TFOS DEWS II definition and classification report. *Ocul Surf* 2017;15(3):276–83.
- [2] Craig JP, Chen YH, Turnbull PR. Prospective trial of intense pulsed light for the treatment of meibomian gland dysfunction. *Invest Ophthalmol Vis Sci* 2015;56(3):1965–70.
- [3] Vora GK, Gupta PK. Intense pulsed light therapy for the treatment of evaporative dry eye disease. *Curr Opin Ophthalmol* 2015;26(4):314–8.
- [4] Gupta PK, Vora GK, Matossian C, Kim M, Stinnett S. Outcomes of intense pulsed light therapy for treatment of evaporative dry eye disease. *Can J Ophthalmol* 2016;51(4):249–53.
- [5] Vegunta S, Patel D, Shen JF. Combination therapy of intense pulsed light therapy and meibomian gland expression (IPL/MGX) can improve dry eye symptoms and meibomian gland function in patients with refractory dry eye: a retrospective analysis. *Cornea* 2016;35(3):318–22.
- [6] Jiang X, Lv H, Song H, Zhang M, Liu Y, Hu X, et al. Evaluation of the safety and effectiveness of intense pulsed light in the treatment of meibomian gland dysfunction. *J Ophthalmol* 2016;2016:1910694.
- [7] Dell SJ, Gaster RN, Barbarino SC, Cunningham DN. Prospective evaluation of intense pulsed light and meibomian gland expression efficacy on relieving signs and symptoms of dry eye disease due to meibomian gland dysfunction. *Clin Ophthalmol* 2017;11:817–27.
- [8] Dell SJ. Intense pulsed light for evaporative dry eye disease. *Clin Ophthalmol* 2017;11:1167–73.
- [9] Rong B, Tu P, Tang Y, Liu RX, Song WJ, Yan XM. Evaluation of short-term effect of intense pulsed light combined with meibomian gland expression in the treatment of meibomian gland dysfunction. *Zhonghua Yan Ke Za Zhi* 2017;53(9):675–81.
- [10] Liu R, Rong B, Tu P, Tang Y, Song W, Toyos R, et al. Analysis of cytokine levels in tears and clinical correlations after intense pulsed light treating meibomian gland dysfunction. *Am J Ophthalmol* 2017;183:81–90.
- [11] Guilloto Caballero S, Garcia Madrona JL, Colmenero Reina E. Effect of pulsed laser light in patients with dry eye syndrome. *Arch Soc Esp Ophthalmol* 2017;92(11):509–15.
- [12] Yin Y, Liu N, Gong L, Song N. Changes in the meibomian gland after exposure to intense pulsed light in meibomian gland dysfunction (MGD) patients. *Curr Eye Res* 2017:1–6.
- [13] Albietsz JM, Schmid KL. Intense pulsed light treatment and meibomian gland expression for moderate to advanced meibomian gland dysfunction. *Clin Exp Optom* 2018;101(1):23–33.
- [14] Rong B, Tang Y, Tu P, Liu R, Qiao J, Song W, et al. Intense pulsed light applied directly on eyelids combined with meibomian gland expression to treat meibomian

- gland dysfunction. *Photomed Laser Surg* 2018;36(6):326–32.
- [15] Arita R, Morishige N, Fujii T, Fukuoka S, Chung JL, Seo KY, et al. Tear interferometric patterns reflect clinical tear dynamics in dry eye patients. *Invest Ophthalmol Vis Sci* 2016;57(8):3928–34.
- [16] Arita R, Morishige N, Koh S, Shirakawa R, Kawashima M, Sakimoto T, et al. Increased tear fluid production as a compensatory response to meibomian gland loss: a multicenter cross-sectional study. *Ophthalmology* 2015;122(5):925–33.
- [17] Nelson JD, Shimazaki J, Benitez-del-Castillo JM, Craig JP, McCulley JP, Den S, et al. The international workshop on meibomian gland dysfunction: report of the definition and classification subcommittee. *Invest Ophthalmol Vis Sci* 2011;52(4):1930–7.
- [18] Lemp MA, Crews LA, Bron AJ, Foulks GN, Sullivan BD. Distribution of aqueous-deficient and evaporative dry eye in a clinic-based patient cohort: a retrospective study. *Cornea* 2012;31(5):472–8.
- [19] Maskin SL. Intraductal meibomian gland probing relieves symptoms of obstructive meibomian gland dysfunction. *Cornea* 2010;29(10):1145–52.
- [20] Greiner JV. A single LipiFlow(R) Thermal Pulsation System treatment improves meibomian gland function and reduces dry eye symptoms for 9 months. *Curr Eye Res* 2012;37(4):272–8.
- [21] Fukuoka S, Arita R. Increase in tear film lipid layer thickness after instillation of 3% diquafosol ophthalmic solution in healthy human eyes. *Ocul Surf* 2017;15(4):730–5.
- [22] Raulin C, Greve B, Grema H. IPL technology: a review. *Laser Surg Med* 2003;32(2):78–87.
- [23] Wat H, Wu DC, Rao J, Goldman MP. Application of intense pulsed light in the treatment of dermatologic disease: a systematic review. *Dermatol Surg* 2014;40(4):359–77.
- [24] Toyos R, McGill W, Briscoe D. Intense pulsed light treatment for dry eye disease due to meibomian gland dysfunction; a 3-year retrospective study. *Photomed Laser Surg* 2015;33(1):41–6.
- [25] Arita R, Mizoguchi T, Fukuoka S, Morishige N. Multicenter study of intense pulsed light therapy for patients with refractory meibomian gland dysfunction. *Cornea* 2018 Nov 8. (in press).
- [26] Amano S, Arita R, Kinoshita S. Group. IJDESMGDW. Definition and diagnostic criteria for meibomian gland dysfunction. *Atarashii Ganka (J Eye)* 2010;27:627–31.
- [27] Shimazaki J, Sakata M, Tsubota K. Ocular surface changes and discomfort in patients with meibomian gland dysfunction. *Arch Ophthalmol* 1995;113(10):1266–70.
- [28] Fitzpatrick TB. The validity and practicality of sun-reactive skin types I through VI. *Arch Dermatol* 1988;124(6):869–71.
- [29] Finis D, Pischel N, Schrader S, Geerling G. Evaluation of lipid layer thickness measurement of the tear film as a diagnostic tool for Meibomian gland dysfunction. *Cornea* 2013;32(12):1549–53.
- [30] Arita R, Minoura I, Morishige N, Shirakawa R, Fukuoka S, Asai K, et al. Development of definitive and reliable grading scales for meibomian gland dysfunction. *Am J Ophthalmol* 2016;169:125–37.
- [31] van Bijsterveld OP. Diagnostic tests in the Sicca syndrome. *Arch Ophthalmol* 1969;82(1):10–4.
- [32] Arita R, Itoh K, Inoue K, Amano S. Noncontact infrared meibography to document age-related changes of the meibomian glands in a normal population. *Ophthalmology* 2008;115(5):911–5.
- [33] Shimer O. Studium zur Physiologie und Pathologie der Tranenabsonderung und Tranenabfuhr. von Graefes *Arch Ophthalmol* 1903;56:197–291.
- [34] Korb DR, Blackie CA, McNally EN. Evidence suggesting that the keratinized portions of the upper and lower lid margins do not make complete contact during deliberate blinking. *Cornea* 2013;32(4):491–5.
- [35] Ngo W, Situ P, Keir N, Korb D, Blackie C, Simpson T. Psychometric properties and validation of the standard patient evaluation of eye dryness questionnaire. *Cornea* 2013;32(9):1204–10.
- [36] Tsubota K, Yokoi N, Shimazaki J, Watanabe H, Dogru M, Yamada M, et al. New perspectives on dry eye definition and diagnosis: a consensus report by the Asia dry eye society. *Ocul Surf* 2017;15(1):65–76.
- [37] Meibomian SRG. Glands in chronic blepharconjunctivitis. *Am J Ophthalmol* 1921;4(249):489–94.
- [38] Korb DR, Greiner JV. Increase in tear film lipid layer thickness following treatment of meibomian gland dysfunction. *Adv Exp Med Biol* 1994;350:293–8.
- [39] Lee H, Kim M, Park SY, Kim EK, Seo KY, Kim TI. Mechanical meibomian gland squeezing combined with eyelid scrubs and warm compresses for the treatment of meibomian gland dysfunction. *Clin Exp Optom* 2017;100(6):598–602.
- [40] Schroeter CA, Haaf-von Below S, Neumann HA. Effective treatment of rosacea using intense pulsed light systems. *Dermatol Surg* 2005;31(10):1285–9.
- [41] de Godoy CH, Silva PF, de Araujo DS, Motta LJ, Biasotto-Gonzalez DA, Politti F, et al. Evaluation of effect of low-level laser therapy on adolescents with temporomandibular disorder: study protocol for a randomized controlled trial. *Trials* 2013;14:229.
- [42] Irvine J, Chong SL, Amirjani N, Chan KM. Double-blind randomized controlled trial of low-level laser therapy in carpal tunnel syndrome. *Muscle Nerve* 2004;30(2):182–7.
- [43] Farrell HP, Garvey M, Cormican M, Laffey JG, Rowan NJ. Investigation of critical inter-related factors affecting the efficacy of pulsed light for inactivating clinically relevant bacterial pathogens. *J Appl Microbiol* 2010;108(5):1494–508.
- [44] Pflugfelder SC, Tseng SC, Sanabria O, Kell H, Garcia CG, Felix C, et al. Evaluation of subjective assessments and objective diagnostic tests for diagnosing tear-film disorders known to cause ocular irritation. *Cornea* 1998;17(1):38–56.