

Analysis of Cytokine Levels in Tears and Clinical Correlations After Intense Pulsed Light Treating Meibomian Gland Dysfunction



RUIXING LIU, BEI RONG, PING TU, YUN TANG, WENJING SONG, ROLANDO TOYOS, MELISSA TOYOS, AND XIAOMING YAN

- **PURPOSE:** To investigate the change from baseline of inflammatory markers in tears of dry eye disease (DED) subjects owing to meibomian gland dysfunction (MGD) after intense pulsed light (IPL) treatment and meibomian gland expression (MGE) compared to sham treatment, and the correlations with ocular surface parameters.
- **DESIGN:** Randomized, double-masked, controlled study.
- **METHODS:** Those randomized into the active treatment arm received 3 consecutive treatments (14~16 J/cm²) approximately 4 weeks apart in the periocular region. Control eyes received 3 treatments in the same intervals of 0 J/cm². Tear samples in all eyes were collected and analyzed at baseline, week 12, and/or week 4 for interleukin (IL)-17A, IL-6, and prostaglandin E2 (PGE2). The correlations between cytokines and ocular surface parameters were analyzed before and after IPL treatment.
- **RESULTS:** All of the inflammatory markers declined in value compared to baselines. IL-17A and IL-6 showed statistically significant decreases compared to sham treatment at each measured time point. PGE2 showed statistically significant decreases compared to sham at week 12. Results showed that the expressions of IL-17A and IL-6 correlated well with ocular surface parameters of the lower eyelid before IPL. The changed values of IL-6 and PGE2 in tears correlated with the changed values of partial ocular surface parameters after IPL treatment in study eyes, respectively.
- **CONCLUSIONS:** The study results suggest that IPL can significantly reduce inflammatory markers in tears of patients suffering with DED owing to MGD after IPL treatment. These findings indicate that IL-17A and IL-6 play roles in the pathogenesis of DED owing to MGD, and the reduction of the inflammatory factors is consistent with the improvement of partial clinical symptoms and signs. (Am J Ophthalmol 2017;183:81–90. © 2017

The Authors. Published by Elsevier Inc. This is an open access article under the CC BY-NC-ND license (<http://creativecommons.org/licenses/by-nc-nd/4.0/>).

DRY EYE DISEASE (DED) ATTRIBUTABLE TO MEIBOMIAN gland dysfunction (MGD) represents a common and growing public health issue, particularly in older adults. MGD is a common cause of evaporative dry eye, affecting almost 70% of the population in some parts of the world, especially in Asia.¹ Meibomian glands are the largest sebaceous glands in the human body. Meibomian glands synthesize and secrete a mixture of lipids, termed meibomian oil or meibum,^{2,3} which is delivered as a clear liquid via orifices located directly in front of the mucocutaneous junction. MGD produces an abnormal meibum that becomes more stagnant than the usual clear liquid secretions.^{4,5} MGD and associated evaporative tear loss is followed by increasing inflammation on the surface of the eye and bacterial overgrowth, as abnormal lipids can provide a rich substrate for the resident bacterial microbiota. The subsequent release of toxic bacterial products, such as lipases, and the production and release of proinflammatory cytokines are pathogenic. This malfunction leads to worsening of abnormal meibum, discomfort, and further derangements of the ocular surface and tear film. Although there are different pathogenic mechanisms responsible for DED owing to MGD, evidence increasingly suggests that all forms of MGD are characterized by varying ocular surface inflammation.^{6,7} Many investigators have reported that the chronic inflammatory status in patients with MGD is associated with high concentrations of tear cytokines.^{8–12} Currently approved topical medications for dry eye, such as cyclosporine and lifitegrast, target inflammation on the ocular surface.^{13,14}

Intense pulsed light (IPL) therapy uses light energy to affect the skin surface, and is widely used in dermatology to treat a variety of conditions, including facial rosacea, port wine stains, seborrheic keratosis, and hypertrophic scar.¹⁵ In addition, the IPL device emits energy in a band from a base of the visible spectrum (580 nm) to near-infrared (1200 nm).¹⁶ Concurrent ocular surface health improvements have been observed serendipitously in



Supplemental Material available at AJO.com.

Accepted for publication Aug 23, 2017.

From the Departments of Ophthalmology (R.L., B.R., Y.T., W.S., X.Y.) and Dermatology (P.T.), Peking University First Hospital, Beijing, China; and Toyos Clinic, Germantown, Tennessee (R.T., M.T.).

Inquiries to Xiaoming Yan, Department of Ophthalmology, Peking University First Hospital, Beijing 100034, P. R. China; e-mail: yanxiaoming7908@163.com

patients undergoing IPL for the dermatologic manifestations of rosacea, leading to interest in evaluating IPL as a potential therapy for DED owing to MGD. There has been a growing number of physicians across the world that use IPL to treat MGD and dry eye.^{17,18} Recently, researchers demonstrated that IPL with multiple sculpted pulses showed therapeutic potential for DED owing to MGD, improving tear film quality and reducing symptoms of dry eye.^{19,20}

There are several related speculative mechanisms whereby IPL treatment is believed to improve signs and symptoms of DED owing to MGD. First, IPL produces heat that is transferred to the thin periorcular skin, which allows the softening of meibum, aids expression, and melts pathologically dysfunctional secretions.¹⁷ Second, the IPL device emits energy that is preferentially absorbed by chromophores in hemoglobin, closing abnormal vasculature in the eyelid margin and adjacent conjunctiva and preventing abnormal vessels from local release of inflammatory factors.^{16,21} Third, IPL therapy may exert an effect in relief of inflammatory and neurogenic pain,²² which is highly related to the improvement of clinical symptoms of DED owing to MGD. Lastly, the IPL treatment can immediately reduce bacteria loads of the eyelid margin and the surrounding adnexa and the associated inflammation caused by them.²³ Despite the many anecdotal case reports outlining efficacy of IPL treatments in dry eye,¹⁷ research quantifying the reduction in specific inflammatory markers during and after IPL treatment is still sparse.

There is mounting evidence that inflammation plays a key role in the pathogenesis of the ocular surface disease that develops in dry eye.²⁴ Interleukin (IL)-17A is a proinflammatory cytokine produced by T-helper cells and the most commonly investigated member of the IL-17 family.⁹ There is an important role for IL-17 in dry eye inflammation processes.²⁵ IL-17 and IL-6 have both been studied as a possible connection between inflammation and ocular surface parameters in DED.^{11,12,25} Further, prostaglandin E2 (PGE2) levels were shown to be higher in tears of MGD patients than in the normal controls.²⁶ In this study, we compared the levels of all 3 inflammatory markers—IL-17A, IL-6, and PGE2—in tears of subjects suffering with DED owing to MGD before, during, and after MGE combined with either IPL or sham treatments so as to evaluate the efficacy of IPL in reducing tear film cytokines. Additionally, we analyzed inflammatory factor levels in tears and clinical correlations after IPL treating DED owing to MGD.

METHODS

• **SUBJECTS:** This randomized, double-masked, controlled clinical trial was conducted in compliance with the principles of the Declaration of Helsinki for the protection of

human subjects in medical research and was approved by the Human Research and Ethics Committee of Peking University First Hospital before the study began. All participants signed written informed consent forms before enrollment. The study was registered at <http://www.chictr.org.cn> (Study no ChiCTR-INR-16010256).

Subjects were recruited from the outpatient department of the Department of Ophthalmology of Peking University First Hospital from February 2016 to March 2016, and the study was conducted in April 2016. The eyes of subjects were randomized into study or control arms. The inclusion criteria^{17,27–29} for this study were (1) adult patients over the age of 18; (2) evidence of meibomian gland obstruction (based on a meibomian gland secretion score of ≤ 12 for 15 glands of the lower lid); (3) Standard Patient Evaluation of Eye Dryness (SPEED) ≥ 6 in both eyes; (4) Fitzpatrick skin type 1–4. Meibomian gland secretion score was measured using the meibomian gland evaluator (Tear Science Inc., Morrisville, North Carolina, USA). The procedure was performed following Lane protocol,²⁷ 15 glands, in both upper and lower eyelids, were evaluated. For each of these glands, the secretion was graded as follows: 0 = no secretion; 1 = inspissated/toothpaste consistency; 2 = cloudy liquid secretion; and 3 = clear liquid secretion. The scores were then summed to a single meibomian gland yield secretion score (MGYSS). The SPEED questionnaire was used to evaluate the severity and frequency of dry eye symptoms.²⁸ Exclusion criteria included (1) patients with any intraocular inflammatory condition, ocular surgery, or trauma in the past 6 months; (2) patients with present ocular infection or allergy; (3) patients with any eyelid structural abnormality; (4) patients with any systemic disease that could lead to DED; (5) if subjects were unable to stop using medication that may lead to DED; (6) patients currently being treated with punctal plugs; (7) patients who tanned in the past 4 weeks; (8) patients with skin cancer or pigment lesion in the treatment zone; (9) subjects who were pregnant/nursing; (10) any systemic or local conditions that researcher considered inappropriate for the trial. Qualifying subjects stopped all topical or oral dry eye medications, artificial tears, and interventions 2 weeks before the baseline examination.

Eighty-eight eyes of 44 patients with DED owing to MGD (12 male and 32 female) were enrolled into this prospective study, with a mean age of 46.3 ± 16.9 years (range 23–86 years).

• **INTERVENTION PROCEDURE:** The study and control eyes of subjects were randomized according to the random number table by the dermatologist (P.T.), who completed the IPL treatments with the M22 system (Lumenis, Tel Aviv, Israel). Before treatment, the subjects received topical tetracaine/lidocaine cream (compound lidocaine cream; Ziguang Pharmaceutical Co, Ltd, Beijing, China) to periorcular treatment areas for 30 minutes (surface

anesthesia) and topical ophthalmic oxybuprocaine hydrochloride eye drops (Benoxil; Santen Pharmaceutical Co, Ltd, Osaka, Japan) into the conjunctival sac 5 minutes before treatment. The study eyes received IPL treatment ($14\sim 16\text{ J/cm}^2$) depending on the Fitzpatrick skin type per the Toyos protocol, followed by MGE on both the upper and lower eyelids using the Arita meibomian gland compressor (Katena Products, Inc, Denville, New Jersey, USA) with no heat. Control eyes received sham IPL treatment (0 J/cm^2), followed by the same MGE. Handheld flashlights were used to simulate light flicker during IPL therapy in the treatment of the control eyes. IPL treatment was administered to the periocular tissues in 6 treatment areas from the nasal to the temporal side on each eyelid, for a total of 3 treatments approximately every 4 weeks.¹⁹ Patients received a total of 12 overlapping IPL pulses in the periocular areas ($8\text{ mm} \times 15\text{ mm}$ each) on the upper and lower eyelids (Figure 1). Subjects received 1 full pass with overlapping flashes to ensure treatment of the entire area. All treatment areas were identical within different subjects. Prior to light treatment, protective metal shields were placed over the cornea and sclera. During the follow-up period of IPL treatment, all subjects used polyethylene glycol eye drops 3 times a day (Systane ULTRA, Alcon Company, Fort Worth, Texas, USA).

- **OCULAR SURFACE PARAMETERS:** The primary outcome measure was meibomian gland assessment (MGA), measured using the meibomian gland evaluator. Evaluation indicators were the number of meibomian glands yielding liquid secretion (MGYLS) and the number of meibomian glands yielding clear secretion (MGYCS). The scores were then summed to a single-score MGYSS according to the above grading standards, termed u-MGYLS/MGYCS/MGYSS for the upper lid and d-MGYLS/MGYCS/MGYSS for the lower lid.²⁷

SPEED questionnaire and ocular surface disease index (OSDI) were used to evaluate the severity and frequency of dry eye symptoms. Tear breakup time (TBUT) was measured using moist fluorescein sodium strips (Jingming New Technological Development Co, Ltd, Tianjin, China). After the fluorescein was instilled into the conjunctival sac, the patient was asked to blink several times. Then the tear film was observed under the cobalt blue filter during biomicroscopy. The average TBUT of 3 repeated measurements was recorded for each eye. Following the TBUT measurement, the corneal fluorescent staining (CFS) was measured. The cornea was divided into 4 quadrants. Each quadrant was graded on a scale of 0 to 3³⁰ (0 = no punctate staining, 1 = 1–30 instances of punctate staining, 2 = punctate staining >30 but no infused lesions, 3 = infused lesions or ulcer). Total CFS of 4 quadrants ranged from 0 to 12.

- **TEAR SAMPLE COLLECTION AND ANALYSIS:** Tear samples were collected by instilling 60 μL of phosphate-




FIGURE 1. Intense pulsed light treatment zone included 6 overlapping periocular areas ($8\text{ mm} \times 15\text{ mm}$ each) on each eyelid.

buffered saline into the inferior fornix without topical anesthetic, followed by movement of the eyes to mix the tear fluid content.³¹ A total of approximately 30 μL of unstimulated tear fluid and buffer were collected from the inferior tear meniscus of each eye using a glass capillary micropipette at the lateral canthus. Samples were placed into a 200- μL Eppendorf tube and immediately transported in an insulated cooler to a -80 C freezer, where they remained frozen until further examination.

Tear cytokines IL-17A and IL-6 concentrations were measured using a multiplex immunobead assay (BDTM Cytometric Bead Array Human Soluble Protein Flex Set; BD Biosciences, San Jose, California, USA) and flow cytometry (BD LSRFortessa; BD Biosciences). The measurements were performed according to protocol.³² Briefly, 10 μL tear fluid was thawed and added to a 50- μL mixture containing each capture antibody–bead reagent and 50 μL detector antibody–phycoerythrin reagent. The mixture was subsequently incubated for 3 hours at room temperature and washed to remove unbound detector antibody–phycoerythrin reagent before flow cytometry. Data were acquired and analyzed using BD Cytometric Bead Array software to calculate the cytokine concentration based on the standard curves and a 5-parameter logistic curve-fitting model with FCAP Array software v3. Flow cytometry was performed using the BD LSRFortessa system (BD Bioscience). The lower limits of detection were the following: IL-17A, 0.3 pg/mL (Human IL-17A Flexset, 560383; BD Biosciences); IL-6, 1.6 pg/mL (Human IL-6 Flexset, 558276; BD Biosciences). The lowest cytokine concentration in the linear portion of the standard curve was used for statistical comparison of tear samples with concentrations of less than this level.

Tear concentrations of PGE2 were measured using a PGE2 ELISA kit (ab133021; Abcam Inc, Cambridge, Massachusetts, USA) according to the manufacturer's instructions. The diluted tear samples (100 μL) was placed in a 96-well goat anti-mouse IgG-coated plate and incubated for 2 hours. After incubation, the plate was washed using the provided washing buffer, and the color was developed

by adding PNPP (200 μ L) substrate after 45 minutes. The amount of PGE2 was acquired and calculated using Gen5 2.04.11 software, which calculates the cytokine concentration based on the standard curves, and a 4-parameter logistic curve-fitting model with ELISACalc. ELISA was performed using the BioTekEpoch (1311227; BioTek Instruments, Inc, Winooski, Vermont, USA). According to the manufacturer, the assay's lower limit of detection was 13.4 pg/mL.

We collected tear samples of both eyes at baseline prior to treatment, on week 4, and on week 12 for each subject. Then, we selected the baseline, week 4, and week 12 points to analyze the levels of cytokines IL-17A and IL-6 in the tear samples; the baseline and week 12 points were selected for analysis of the PGE2 concentration.

- **STATISTICAL ANALYSIS:** Data are expressed as mean \pm standard error of the mean (SEM). Analysis between 2 different time points (week 4 and week 12) for single variable data was performed using a paired-samples test with SPSS 17.0 for Windows software (SPSS Inc, Armonk, New York, USA). To compare the change in cytokine concentration in tears of study eyes with control eyes at individual time points, a paired-samples test was used. Correlations between the expressions of cytokines and ocular surface parameters, and between their changed values after IPL treatment, were analyzed by Spearman correlation coefficient, respectively. For all tests, $P < .05$ was considered to be statistically significant.

RESULTS

- **INTENSE PULSED LIGHT DOWNREGULATES THE LEVEL OF INTERLEUKIN 17A IN TEARS OF PATIENTS WITH DRY EYE DISEASE OWING TO MEIBOMIAN GLAND DYSFUNCTION:** The changed values of cytokine IL-17A level in tears on week 4 and week 12 after IPL treatment in the study eyes were -173.49 ± 32.26 and -211.75 ± 33.78 pg/mL, respectively ($n = 44$, mean \pm SEM). The IL-17A levels of the control eyes were -64.64 ± 24.12 and -89.61 ± 22.21 pg/mL, respectively. All values represent a decrease from the pretreatment baselines. As shown in Figure 2, IL-17A was more significantly reduced in the IPL treatment arm than in the control after both week 4 and week 12 of IPL treatment (both $P < .001$). The value of IL-17A was most significantly decreased at the final study time point after 3 IPL treatments at week 12 compared to week 4 of IPL treatment in the treatment arm (Figure 2, $P < .001$). However, in the control eyes, no significant differences were found between the measured values of IL-17A at week 4 and week 12 of IPL treatment (Figure 2, $P = .068$).

- **INTENSE PULSED LIGHT DOWNREGULATES THE LEVEL OF INTERLEUKIN 6 IN TEARS OF PATIENTS WITH DRY**

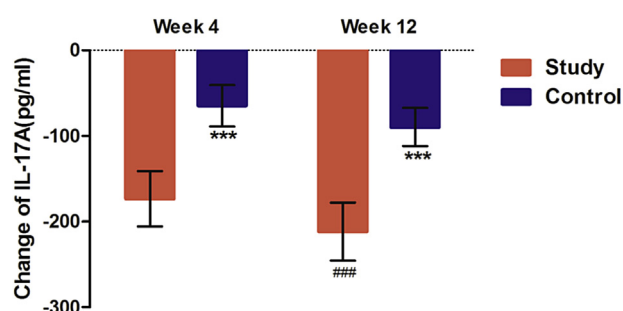


FIGURE 2. Intense pulsed light (IPL) downregulates the level of interleukin (IL)-17A in tears of patients with dry eye disease owing to meibomian gland dysfunction (MGD). IL-17A change to baseline. Baseline corrected change of the level of IL-17A (week 4 minus baseline; week 12 minus baseline). The mean changed value of tear IL-17A level (pg/mL) after week 4 and week 12 of IPL treatment in the study eyes and the control eyes (mean \pm SEM, $n = 44$) is shown. *** $P < .001$ compared to the study eyes at the same time point including week 4 and week 12. ### $P < .001$ compared to week 4 in the study eyes. Bars designate the means with 95% confidence intervals. Week 4: difference value between pretreatment and week 4 after IPL treatment; Week 12: difference value between pretreatment and week 12 after IPL treatment.

- **EYE DISEASE OWING TO MEIBOMIAN GLAND DYSFUNCTION:** The changed values of cytokine IL-6 level in tears at week 4 and week 12 after IPL treatment in the study eyes were -308.35 ± 58.59 and -405.62 ± 65.61 pg/mL, respectively ($n = 44$, mean \pm SEM). The IL-6 levels of the control eyes were -50.61 ± 22.08 and -143.46 ± 25.99 pg/mL (in the order designated above). These numbers represented a decrease from the pretreatment baselines. Compared to the control eyes, the value of IL-6 was significantly more decreased in the study eyes after week 4 and week 12 of IPL treatment (Figure 3, both $P < .01$). Like IL-17A, IL-6 levels were most significantly lowered after week 12 compared to week 4 (Figure 3, $P < .01$).

- **INTENSE PULSED LIGHT DOWNREGULATES THE LEVEL OF PROSTAGLANDIN E2 IN TEARS OF PATIENTS WITH DRY EYE DISEASE OWING TO MEIBOMIAN GLAND DYSFUNCTION:** The changed concentration of PGE2 in tears at week 12 after IPL treatment in the study eyes was -1.64 ± 0.14 ng/mL ($n = 44$, mean \pm SEM). The PGE2 level of the control eyes at the same time point was -0.73 ± 0.13 ng/mL ($n = 44$, mean \pm SEM). Both numbers represent a decrease from the pretreatment baselines. Compared to the control eyes, the mean concentration of PGE2 was more significantly decreased in the study eyes after week 12 of IPL treatment (Figure 4, $P < .001$).

- **CORRELATIONS BETWEEN CYTOKINES AND OCULAR SURFACE PARAMETERS IN PATIENTS WITH DRY EYE DISEASE OWING TO MGD BEFORE INTENSE PULSED LIGHT**

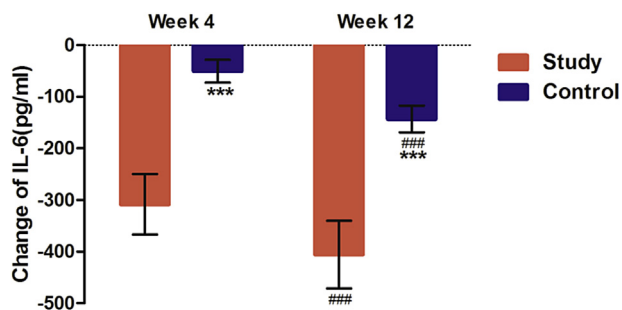


FIGURE 3. Intense pulsed light (IPL) downregulates the level of interleukin (IL)-6 in tears of patients with dry eye disease owing to meibomian gland dysfunction. IL-6 change to baseline. Baseline corrected change of the level of IL-6 (week 4 minus baseline; week 12 minus baseline). The mean changed value of IL-6 (pg/mL) after week 4 and week 12 of IPL treatment in the study eyes and the control eyes (mean ± SEM, n = 44) is shown. *** $P < .001$ compared to the study eyes at the same time point including week 4 and week 12. ### $P < .001$ compared to week 4 in both eyes. Values are expressed as picograms (means ± SEM pg/mL). Bars designate the means with 95% confidence intervals. Week 4: difference value between pretreatment and week 4 after IPL treatment; Week 12: difference value between pretreatment and week 12 after IPL treatment.

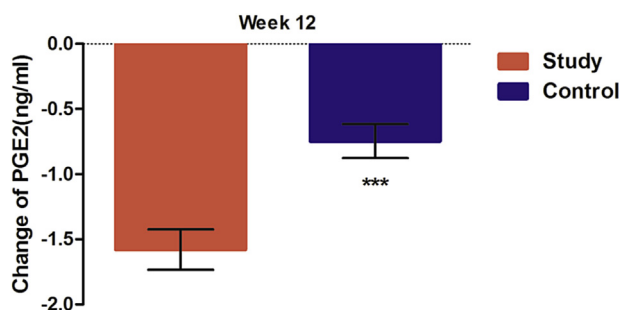


FIGURE 4. Intense pulsed light (IPL) downregulates the level of prostaglandin E2 (PGE2) in tears of patients with dry eye disease owing to meibomian gland dysfunction. PGE2 change to baseline. Baseline corrected change of the level of PGE2 (week 12 minus baseline). The mean changed value of PGE2 (ng/mL) after week 12 (in the IPL treatment endpoint) of IPL treatment in the study eyes and the control eyes (mean ± SEM, n = 44) is shown. *** $P < .001$ compared to the study eyes in the IPL treatment endpoint. Values are expressed as nanograms (means ± SEM, ng/mL). Bars designate the means with 95% confidence intervals. Week 12: difference value between pretreatment and week 12 after IPL treatment.

TREATMENT: The correlations between the expressions of IL-17A, IL-6, and PGE2 and ocular surface parameters of 44 subjects were evaluated in protein levels. One eye was randomly selected for statistical analysis. The correlation analysis between the expression of IL-17A and IL-6 in protein levels and some ocular surface parameters (SPEED,

OSDI, BUT, and CFS) showed no statistical significance (all $P > .05$). The correlation analysis between the expression of PGE2 in protein levels and any ocular surface parameter showed no statistical significance (all $P > .05$). On the other hand, the levels of IL-17A in tears correlated well with d-MGYLS ($R = -0.680, P < .001$; Figure 5, Top left), d-MGYCS ($R = -0.44, P = .003$; Figure 5, Top center), and d-MGYSS ($R = -0.692, P < .001$; Figure 5, Top right) at the pretreatment baselines. The levels of IL-6 in tears correlated well with d-MGYLS ($R = -0.839, P < .001$; Figure 5, Bottom left), d-MGYCS ($R = -0.446, P = .002$; Figure 5, Bottom center), and d-MGYSS ($R = -0.845, P < .001$; Figure 5, Bottom right) at the pretreatment baselines.

- **CORRELATIONS BETWEEN THE CHANGED VALUES OF CYTOKINES AND THE CHANGED VALUES OF OCULAR SURFACE PARAMETERS AFTER INTENSE PULSED LIGHT TREATING PATIENTS WITH DRY EYE DISEASE OWING TO MEIBOMIAN GLAND DYSFUNCTION:** Baseline corrected change of the levels of cytokines and ocular surface parameters (week 12 minus baseline) represented a decrease from the pretreatment baselines. The correlations between the changed values of IL-17A, IL-6, PGE2, and ocular surface parameters of 44 subjects were evaluated in protein levels. The correlation analysis between the changed values of IL-17A, IL-6, and PGE2 in protein levels and the changed values of any ocular surface parameter showed no statistical significance (all $P > .05$) in control eyes. On the other hand, the changed value of IL-6 in tears correlated with the changed value of d-MGYCS ($R = -0.411, P = .006$; Figure 6, Left) after IPL treatment in study eyes. The changed level of PGE2 in tears correlated with that of CFS ($R = 0.311, P = .040$; Figure 6, Right) after IPL treatment in study eyes.

DISCUSSION

MEIBOMIAN GLAND DYSFUNCTION IS A HIGHLY PREVALENT and growing ocular surface condition with potential to create long-term damage to the ocular surface. Current therapies for DED with or without MGD remain nonpermanent and many patients experience side effects or incomplete resolution, prompting researchers to continue exploration of more effective therapeutic approaches. IPL therapy, which has been used extensively in dermatology to treat chronic skin conditions including rosacea, is a relatively new treatment in ophthalmology for patients with evaporative DED.¹⁵ Although there are very few studies published on the use of IPL in patients to reduce the signs and symptoms of DED owing to MGD, IPL therapy has promising results for these patients. Previous reports outline statistically significant improvements in symptoms and clinical examination findings of dry eye owing to MGD.¹⁸ It is helpful to continue to build knowledge in

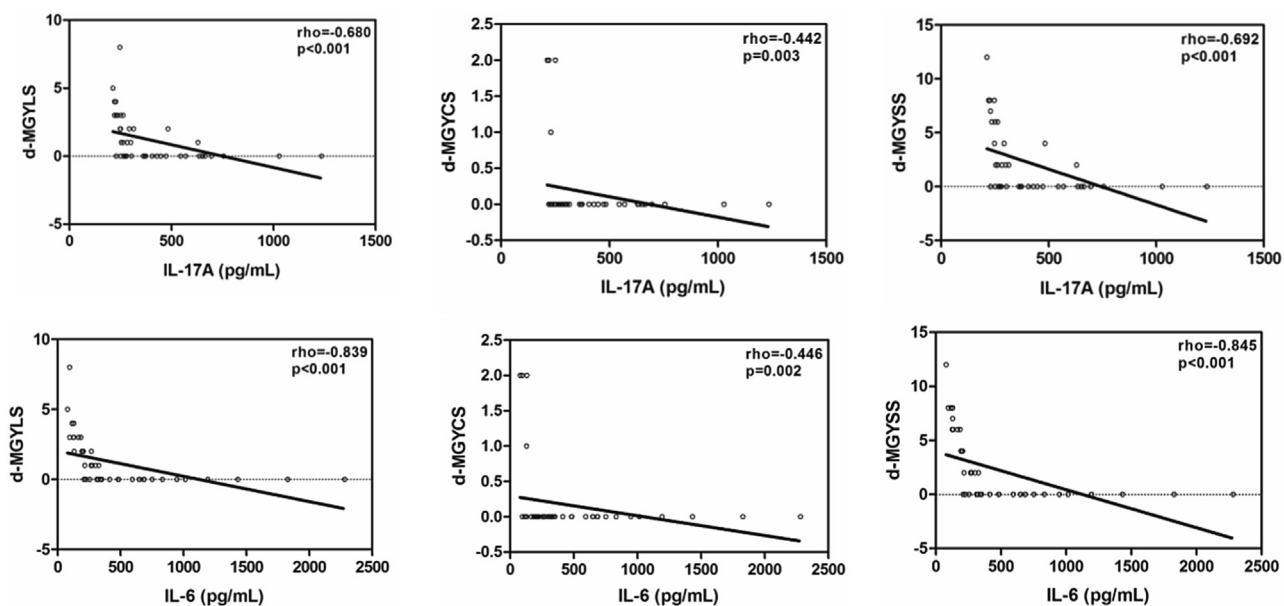


FIGURE 5. Correlations between cytokines (interleukin [IL]-17A and IL-6) and ocular surface parameters in patients with dry eye disease owing to meibomian gland dysfunction before intense pulsed light treatment. Correlation between levels of IL-17A and IL-6 in tears and ocular surface parameters including (at lower lid) number of meibomian glands yielding liquid secretion (d-MGYLS; Top left, Bottom left), number of meibomian glands yielding clear secretion (d-MGYCS; Top center, Bottom center), and single meibomian gland yield secretion score (d-MGYSS; Top right, Bottom right). The R and P values were determined with Spearman correlation coefficient.

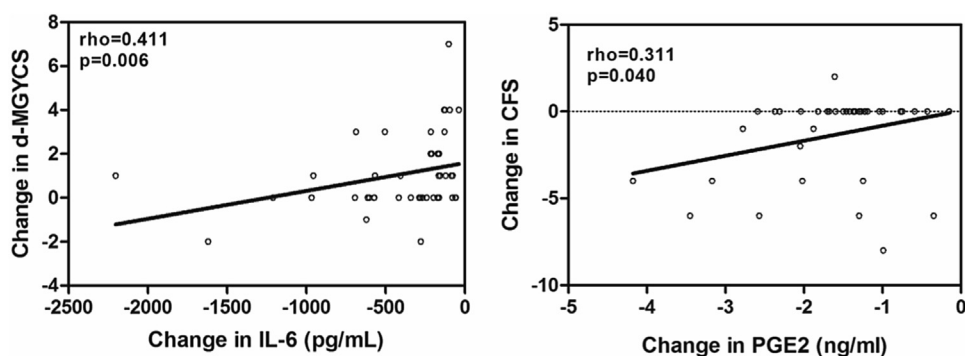


FIGURE 6. Correlations between the changed values of cytokines (interleukin [IL]-6 and prostaglandin E2 [PGE2]) and the changed values of ocular surface parameters after intense pulsed light (IPL) treating patients with dry eye disease owing to meibomian gland disease. (Left) Correlations between the changed values of IL-6 and the changed values of number of meibomian glands yielding clear secretion of the lower eyelid (d-MGYCS). (Right) Correlations between the changed values of PGE2 and the changed values of corneal fluorescent staining (CFS). The R and P values were determined with Spearman correlation coefficient.

this area by reporting the change in common ocular surface inflammatory markers owing to MGD alone and also combined with IPL.

Our study showed that IL-17A and IL-6 were significantly decreased in tears from patients with DED owing to MGD after IPL treatment in the study eyes. IL-17A is the most commonly studied member of the IL-17 family, which consists of 6 related proteins, from IL-17A to IL-17F. Th-17 cells are the major source of IL-17A and F, while other cell populations express IL-17A to a lesser

extent. As a result, assessment of IL-17A indicates that Th-17 cells are more likely to be the source cells than other cell populations.⁹ Several reports previously highlighted increased tear inflammatory cytokines such as IL-17 and IL-6 in patients with DED owing to MGD.^{9,11,12,24}

Normal meibum contains antimicrobial properties that keep the lid margin clear from overgrowth.¹⁷ Abnormal blood vessel growth from chronic inflammation (telangiectasias) surround the meibomian glands and leak inflammatory mediators that cause malfunction of the glands.³³ This

dysfunction leads to formation of an abnormal meibum. Eyelid margin telangiectasias are often seen clinically in patients with DED owing to MGD and ocular rosacea. The pathophysiology of rosacea involves thinning of connective tissues, allowing passive dilation of blood vessels (erythema and telangiectasias) and extravasation of inflammatory mediators (causing papules and pustules).¹⁸ IPL allows for selective ablation of these superficial vessels by targeting chromophores in hemoglobin, which not only reduces telangiectasias and erythema but also presumably decreases inflammatory marker access to the meibomian glands.²³ In this research, both IL-17A and IL-6 cytokines were found to be decreased in tears from patients with DED owing to MGD after IPL treatment. Potentially, IPL near the lid should cause closing of the abnormal blood vessels secreting inflammatory mediators, reducing the amount of cytokines IL-17A and IL-6 found in the tears, and also decreasing bacterial overgrowth by disrupting bacterial cell walls with targeted wavelengths of light. Based on this evidence, our data suggest that the decrease of tear IL-17A and IL-6 may correlate with the reduction of signs and symptoms of patients seen in other studies.¹⁷

In our study, the levels of both IL-17A and IL-6 in tears correlated well with d-MGYLS, d-MGYCS, and d-MGYSS at the pretreatment baselines. But, the correlation analysis between the expression of IL-17A and IL-6 in protein levels and SPEED/OSDI showed no statistical significance. Associations between DED signs and symptoms are low and inconsistent, which is consistent with the systematic literature review of the available evidence on associations between clinical signs and symptoms in DED.³⁴ The results of the study found that the indicators of the lower eyelid and inflammation were more related. This suggests that the lower eyelid may be more sensitive to inflammation, compared with the upper eyelid index. The MGA of the lower eyelid as an observation indicator in patients with DED owing to MGD is more meaningful and, combined with the upper eyelid, can be used as screening indicators.

There are some related speculative mechanisms whereby the inflammatory factors in tears are more related to the lower eyelid indexes in patients with DED owing to MGD. First, there are about 25–40 glands (average 31), the length of the central tarsal gland is about 5.5 mm, and the capacity is 26 μL in the upper eyelid tarsal gland, whereas there are about 20–30 glands (average 26), the length of the central tarsal gland is about 2 mm, and the capacity is 13 μL in the lower eyelid tarsal gland. The secretion lipid capacity of the upper eyelid is 2 times that of the lower eyelid. Meibomian glands are anatomically different between upper and lower eyelids and may differ functionally, given that upper eyelids move more prominently than do the lower eyelids during blinking.³⁵ Second, Eom and associates³⁶ mentioned that gravity may lead to meibum stagnancy in the ducts and orifices, with the result that meibum is more difficult and discontinuous to secrete in the lower eyelid than in the upper eyelid. In our study, we noticed that gland secretion

function in the lower eyelids was damaged more seriously than in the upper eyelids (2.3 ± 3.2 vs 9.3 ± 7.5 at the baseline of the study) in study eyes, which is consistent with previous studies.^{37,38} It is presumed that the content of inflammatory factors in tears may be more related to the indexes of the lower eyelid. Third, the upper meniscus filled out fully, and the excess tears were distributed to the lower tear meniscus. Also, tear meniscus height and area of the lower eyelid are greater and wider than the upper eyelid.^{39,40} Coupled with the role of gravity, the lower eyelid may contact the inflammatory factors in the tears for a longer time and in a wider area, and thus lower eyelid damage is more serious. In other words, inflammatory factors can affect the function of the lower eyelid, resulting in the content of inflammatory factors in tears and lower eyelid indexes being more relevant. It is further explained that lower eyelid damage is more serious in patients with DED owing to MGD. So MGA of the lower eyelid as a measure of DED owing to MGD indicators is more meaningful.

The changed value of IL-6 in tears correlated with the changed values of d-MGYCS after IPL treatment in study eyes. This change suggests that the improvement of d-MGYCS is likely to result in a change in the concentration of IL-6 after IPL treatment. The improvement of the lower eyelid gland clear secretion is particularly associated with the level of IL-6. IPL treatment is more relevant to the change in IL-6. In our study, we noticed that the lowered rate of IL-6 changes was greater than that of IL-17A (-84% vs -52% at the end of the study) in study eyes. IL-6 may be associated with an improvement in eyelid gland signs after IPL treatment. This may be because the decline in IL-17A is not large enough and the sample size of the study is too small.

Reductions in the levels of IL-6 and IL-17A were seen at each study time point in both arms of the study. Chauhan and associates showed that blockade of IL-17 significantly reduced the severity and progression of DED in vivo, which was paralleled by a reduction in the expansion of Th17 cells.⁴¹ Assessment of IL-17A indicates that Th-17 cells are more likely to be the source cells than the other cell populations above.⁹ IL-6 also plays a critical role in Th17 cell differentiation.⁴² Further research is needed to determine which marker may be most critical and whether Th17 cells are also changed when DED owing to MGD is treated with IPL.

The data showed that levels of PGE2 were lowered in both the control and the study arms and were lowest in the study group receiving IPL. The changed level of PGE2 in tears correlated with that of CFS after IPL treatment in study eyes. PGE2 is a prostaglandin with a significant role in inflammation.^{43,44} A small amount of PGE2 is likely to be sufficient to elicit and maintain the inflammatory pain state. PGE2 is a key mediator of pain in inflammation,⁴⁴ and its reduction may be responsible for improvement of symptoms in patients receiving IPL

for dry eye. Commonly detectable signs of DED owing to MGD, including tear film instability, evaporative dry eye, and eyelid inflammation, are caused by modified and deficient meibum lipids.⁴⁵ Lipid synthesis processes of the meibomian glands are known to be affected by hormonal (mostly androgen), vascular, and neuronal influences.⁴⁶ PGE2 may be produced by damaged ocular surface cells, induced by microbes present on the surface, or a result of acute and chronic inflammation on the surface of the eye and within abnormal meibomian glands.⁴⁷ The elevated PGE2 in DED patients may aggravate ocular surface inflammation by inducing other inflammatory mediators. The elevated PGE2 may stimulate tear production to overcome surface dryness as well as to elicit irritation symptoms. Reduction in PGE2 levels was also found in the tears of all study patients, but was lowest in the active comparator group receiving IPL. The mechanism by which PGE2 levels are reduced by MGE and IPL is unclear but may be related to reduction in bacterial loads, improvement in meibum quality, decrease in skin inflammation, closure of telangiectasias, and photomodulation of meibomian glands. Further study is warranted to determine the role of PGE2 as a marker in DED owing to MGD.

It is interesting that the lowered levels of IL-17A, IL-6, and PGE2 were seen in the control group at all time points. MGE is known to improve symptoms of dry eye disease.⁴⁸ MGE could increase the meibum secretions, reduce the inflammation reaction of meibomian glands, and then lower the level of the molecules in tear samples. The study results also indicate that IPL treatment combined with MGE is more effective than expression alone. Expression would be expected to initially increase the levels of ocular surface inflammation as abnormal gland secretions are expressed onto the surface and then would be expected to decrease as abnormal secretions make way for healthier oils.

The improved outcomes in inflammatory markers with IPL treatment are likely owing to several mechanisms of action. The wavelength of light used in IPL for patients with DED owing to MGD is partially infrared, which can penetrate skin to the meibomian glands, generating enough heat to melt the solid secretions in the dysfunctional glands.⁴⁹ The M22 model uses the cooling sapphire crystal tip to cool the skin, allowing higher-temperature pulses without epidermal burning.⁵⁰ Secondly, optimized pulse technology (OPT) is a feature on the fifth-generation M22 unit that may confer outcome advantages. The OPT can eliminate energy peak at the beginning of the pulse and increase energy at the end of the pulse, so that the entire energy output can safely and effectively heat the target

tissue to the therapeutic temperature. Homogeneous “squared off” energy distribution provides more reproducible treatments for patients, which is also a feature not in other technologies. Thirdly, the IPL is known to close abnormal telangiectasia in skin rosacea, including ocular rosacea, preventing the continued leakage of cytokines that can perpetuate inflammation. Lastly, and possibly most importantly, the specific wavelengths of light provided by the IPL may also stimulate mitochondria of meibomian glands to function normally through a process known as photomodulation.⁵¹ This is the first published work outlining the study of these inflammatory markers over a typical clinical treatment course.

There are several limitations in this study. The volume of tear samples taken was not enough to analyze more than these 3 inflammatory markers. Many hundreds of inflammatory markers are present in acute and chronic dry eye, and some of these markers may prove to be even more important as markers in this disease. Another limitation is the female preponderance (73%) in our enrolled patients, although it reflects the sex divisions seen in clinical practice. The subjects were also asked to provide a subjective assessment of their eyes one to the other, which could introduce some variability. Lastly, it is possible that the subjects could discern whether and how much light/thermal energy was imparted to them, as there is no practical way to present IPL as a true sham treatment. In future studies, clinicians could potentially test larger volumes of tear samples at more time points and enlarge the sample size to optimize the power of the study.

In conclusion, this research demonstrates the reduction of 3 important ocular surface inflammatory factors—IL-17A, IL-6, and PGE2—indicating that IPL combined with MGE is more effective than MGE alone in reducing inflammation of patients with DED owing to MGD. The expressions of IL-17A and IL-6 in protein levels are consistent with ocular surface parameters of the lower eyelid before IPL treatment. Also, the reduction of the inflammatory factors is consistent with the improvement of partial clinical symptoms and signs (d-MGYCS and CFS). These findings indicate that IL-17A and IL-6 play roles in the pathogenesis of DED owing to MGD, and the IL-6 and PGE2 in tears have potential to be a sign of symptom improvement for IPL treatment in patients with DED owing to MGD. In addition, these data present the possibility of an important new approach for treatment of DED owing to MGD. More studies are required to elucidate other issues related to DED, IPL, and its treatment, including the best inflammatory marker to follow, ideal treatment energies, and number of treatments.

FUNDING/SUPPORT: NO FUNDING OR GRANT SUPPORT. FINANCIAL DISCLOSURES: THE FOLLOWING AUTHORS HAVE NO financial disclosures: Ruixing Liu, Bei Rong, Ping Tu, Yun Tang, Wenjing Song, Rolando Toyos, Melissa Toyos, and Xiaoming Yan. All authors attest that they meet the current ICMJE criteria for authorship.

REFERENCES

1. Schaumberg DA, Nichols JJ, Papas EB, et al. The international workshop on meibomian gland dysfunction: report of the subcommittee on the epidemiology of, and associated risk factors for, MGD. *Invest Ophthalmol Vis Sci* 2011;52:1994–2005.
2. Nicolaides N, Kaitaranta JK, Rawdah TN, et al. Meibomian gland studies: comparison of steer and human lipids. *Invest Ophthalmol Vis Sci* 1981;20:522–536.
3. Ong BL, Larke JR. Meibomian gland dysfunction: some clinical, biochemical and physical observations. *Ophthalmic Physiol Opt* 1990;10:144–148.
4. Korb DR, Blackie CA. Meibomian gland therapeutic expression: quantifying the applied pressure and the limitation of resulting pain. *Eye Contact Lens* 2011;37:298–301.
5. Olson MC, Korb DR, Greiner JV. Increase in tear film lipid layer thickness following treatment with warm compresses in patients with meibomian gland dysfunction. *Eye Contact Lens* 2003;29:96–99.
6. Pflugfelder SC. Anti-inflammatory therapy of dry eye. *Ocul Surf* 2003;1:31–36.
7. Wei Y, Asbell PA. The core mechanism of dry eye disease is inflammation. *Eye Contact Lens* 2014;40:248–256.
8. Lee H, Chung B, Kim KS, Seo KY, Choi BJ, Kim TI. Effects of topical loteprednol etabonate on tear cytokines and clinical outcomes in moderate and severe meibomian gland dysfunction: randomized clinical trial. *Am J Ophthalmol* 2014;158:1172–1183.e1.
9. Kang MH, Kim MK, Lee HJ, et al. Interleukin-17 in various ocular surface inflammatory diseases. *J Korean Med Sci* 2011;26:938–944.
10. Frey AG, Nandal A, Park JH, et al. Iron chaperones PCBP1 and PCBP2 mediate the metallation of the dinuclear iron enzyme deoxyhypusine hydroxylase. *Proc Natl Acad Sci U S A* 2012;111:8031–8036.
11. Acera A, Rocha G, Vecino E, et al. Inflammatory markers in the tears of patients with ocular surface disease. *Ophthalmic Res* 2008;40:315–321.
12. Pflugfelder SC. Tear cytokine profiles in dysfunctional tear syndrome. *Am J Ophthalmol* 2009;147:198–205.e1.
13. Prabhasawat P, Tesavibul N, Mahawong W. A randomized double-masked study of 0.05% cyclosporine ophthalmic emulsion in the treatment of meibomian gland dysfunction. *Cornea* 2012;31:1386–1393.
14. Holland EJ, Luchs J, Karpecki PM, et al. Lifitegrast for the treatment of dry eye disease: results of a phase III, randomized, double-masked, placebo-controlled trial (OPUS-3). *Ophthalmology* 2017;124:53–60.
15. Piccolo D, Di Marcantonio D, Crisman G, et al. Unconventional use of intense pulsed light. *Biomed Res Int* 2014;2014:618206.
16. Schroeter CA, Haaf-von Below S, Neumann HAM. Effective treatment of rosacea using intense pulsed light systems. *Dermatol Surg* 2005;31:1285–1289.
17. Toyos R, McGill W, Briscoe D. Intense pulsed light treatment for dry eye disease due to meibomian gland dysfunction; a 3-year retrospective study. *Photomed Laser Surg* 2015;33:41–46.
18. Vora GK, Gupta PK. Intense pulsed light therapy for the treatment of evaporative dry eye disease. *Curr Opin Ophthalmol* 2015;26:314–318.
19. Craig JP, Chen Y, Turnbull PRK. Prospective trial of intense pulsed light for the treatment of meibomian gland dysfunction. *Invest Ophthalmol Vis Sci* 2015;56:1965–1970.
20. Gupta PK, Vora GK, Matossian C, et al. Outcomes of intense pulsed light therapy for treatment of evaporative dry eye disease. *Can J Ophthalmol* 2016;51:249–253.
21. de Godoy CHL, Silva PF, de Araujo DS, et al. Evaluation of effect of low-level laser therapy on adolescents with temporomandibular disorder: study protocol for a randomized controlled trial. *Trials* 2013;14:229.
22. Irvine J, Chong SL, Amirjani N, Chan KM. Double-blind randomized controlled trial of low-level laser therapy in carpal tunnel syndrome. *Muscle Nerve* 2004;30:182–187.
23. Farrell HPP, Garvey M, Cormican M, et al. Investigation of critical inter-related factors affecting the efficacy of pulsed light for inactivating clinically relevant bacterial pathogens. *J Appl Microbiol* 2010;108:1494–1508.
24. Pflugfelder SC. Antiinflammatory therapy for dry eye. *Am J Ophthalmol* 2004;137:337–342.
25. Lee SY, Han SJ, Nam SM, et al. Analysis of tear cytokines and clinical correlations in Sjögren syndrome dry eye patients and non-Sjögren syndrome dry eye patients. *Am J Ophthalmol* 2013;156:247–253.e1.
26. Shim J, Park C, Lee HS, et al. Change in prostaglandin expression levels and synthesizing activities in dry eye disease. *Ophthalmology* 2012;119:2211–2219.
27. Lane SS, DuBiner HB, Epstein RJ, et al. A new system, the LipiFlow, for the treatment of meibomian gland dysfunction. *Cornea* 2012;31:396–404.
28. Ngo W, Situ P, Keir N, et al. Psychometric properties and validation of the Standard Patient Evaluation of Eye Dryness questionnaire. *Cornea* 2013;32:1204–1210.
29. Blackie CA, Coleman CA, Holland EJ. The sustained effect (12 months) of a single-dose vectored thermal pulsation procedure for meibomian gland dysfunction and evaporative dry eye. *Clin Ophthalmol* 2016;10:1385–1396.
30. Anon. Corneal Disease Group of Ophthalmological Society CMA. Experts' consensus about clinical diagnosis and treatment of dry eye (2013). *Chin J Ophthalmol* 2013;49(1):73–75.
31. Argüeso P, Balaram M, Spurr-Michaud S, et al. Decreased levels of the goblet cell mucin MUC5AC in tears of patients with Sjögren syndrome. *Invest Ophthalmol Vis Sci* 2002;43:1004–1011.
32. Cook EB, Stahl JL, Lowe L, et al. Simultaneous measurement of six cytokines in a single sample of human tears using microparticle-based flow cytometry: allergics vs. non-allergics. *J Immunol Methods* 2001;254:109–118.
33. Geerling G, Tauber J, Baudouin C, et al. The international workshop on meibomian gland dysfunction: report of the subcommittee on management and treatment of meibomian gland dysfunction. *Invest Ophthalmol Vis Sci* 2011;52:2050–2064.
34. Bartlett JD, Keith MS, Sudharshan L, Snedecor SJ. Associations between signs and symptoms of dry eye disease: a systematic review. *Clin Ophthalmol* 2015;9:1719–1730.
35. Knop E, Knop N, Millar T, et al. The international workshop on meibomian gland dysfunction: report of the subcommittee on anatomy, physiology, and pathophysiology of the meibomian gland. *Invest Ophthalmol Vis Sci* 2011;52:1938–1978.

36. Eom Y, Choi K-E, Kang S-Y, et al. Comparison of meibomian gland loss and expressed meibum grade between the upper and lower eyelids in patients with obstructive meibomian gland dysfunction. *Cornea* 2014;33:448–452.
37. Pult H, Riede-Pult BH, Nichols JJ. Relation between upper and lower lids' meibomian gland morphology, tear film, and dry eye. *Optom Vis Sci* 2012;89:E310–E315.
38. Srinivasan S, Menzies K, Sorbara L, Jones L. Infrared imaging of meibomian gland structure using a novel keratograph. *Optom Vis Sci* 2012;89:788–794.
39. Shen M, Li J, Wang J, et al. Upper and lower tear menisci in the diagnosis of dry eye. *Invest Ophthalmol Vis Sci* 2009;50:2722–2726.
40. Wang J, Simmons P, Aquavella J, et al. Dynamic distribution of artificial tears on the ocular surface. *Arch Ophthalmol* 2008;126:619–625.
41. Chauhan SK, El Annan J, Ecoiffier T, et al. Autoimmunity in dry eye is due to resistance of Th17 to Treg suppression. *J Immunol* 2009;182:1247–1252.
42. Lin P, Suhler EB, Rosenbaum JT. The future of uveitis treatment. *Ophthalmology* 2014;121:365–376.
43. Iyer JP, Srivastava PK, Dev R, et al. Prostaglandin E(2) synthase inhibition as a therapeutic target. *Expert Opin Ther Targets* 2009;13:849–865.
44. Ek M, Engblom D, Saha S, et al. Inflammatory response: pathway across the blood-brain barrier. *Nature* 2001;410:430–431.
45. Goto E, Endo K, Suzuki A, et al. Tear evaporation dynamics in normal subjects and subjects with obstructive meibomian gland dysfunction. *Invest Ophthalmol Vis Sci* 2003;44:533–539.
46. McCulley JP, Shine WE. The lipid layer of tears: dependent on meibomian gland function. *Exp Eye Res* 2004;78:361–365.
47. Johnson ME. The association between symptoms of discomfort and signs in dry eye. *Ocul Surf* 2009;7:199–211.
48. Korb DR, Greiner JV. Increase in tear film lipid layer thickness following treatment of meibomian gland dysfunction. *Adv Exp Med Biol* 1994;350:293–298.
49. Terada O, Chiba K, Senoo T, Obara Y. [Ocular surface temperature of meibomia gland dysfunction patients and the melting point of meibomian gland secretions]. *Nihon Ganka Gakkai Zasshi* 2004;108:690–693.
50. Raulin C, Greve B, Grema H. IPL technology: a review. *Lasers Surg Med* 2003;32:78–87.
51. Wong W-R, Shyu W-L, Tsai J-W, et al. Intense pulsed light effects on the expression of extracellular matrix proteins and transforming growth factor beta-1 in skin dermal fibroblasts cultured within contracted collagen lattices. *Dermatol Surg* 2009;35:816–825.